

Digoxin Therapy for Fetal Supraventricular Tachycardia Diagnosed at 29 Weeks Gestation

Nitisha Lath*, Savita Bansal**, Pratibha Singh***

Abstract

Fetal Supraventricular tachycardia (SVT), though rare, is the most commonly encountered clinically significant tachycardia in the fetus. When SVT is sustained, congestive heart failure and fetal hydrops may ensue, due to both systolic and diastolic dysfunction. Sonographic diagnosis is usually incidental during the second or third trimester. Treatment goals are cardioversion to sinus rhythm and reversal of cardiac dysfunction [1]. Digoxin has been successfully used to treat fetal SVT, when therapy with digoxin fails alternative therapies may be used with equivocal results [2]. There is no clear consensus regarding the best drug-treatment regimens for fetal SVT. Digoxin has been recommended as first-line therapy in cases of SVT with cardiac failure, but recent evidence suggests that the transplacental passage may be impaired in the presence of hydrops [3]. Other agents such as flecainide and sotalol have been tried as first-line agents but with adverse events [4].

We here describe a case of fetal supraventricular tachycardia without hydrops diagnosed antenatally at 29 weeks of gestation and managed with oral digoxin.

Introduction

Supraventricular tachycardia (SVT) is a commonly encountered, clinically significant sustained tachycardia in the fetus. The basic underlying mechanism for this

clinically important entity is- either an automatic focus, provoking atrial contractions at a rate faster than the sino-atrial node or the re-entry mechanism in which there is a circular electrical current running between a fast conducting accessory pathway, the ventricle, atrioventricular node and atria in either direction. Supraventricular tachycardia may be part of a cardiac malformation such as Ebstein's anomaly but in majority it is found to be the sole pathology. The usual cardiac contraction rate in SVT is 220-280 bpm, but faster rates than this have been described.⁵ When such rates are sustained, diastole is shortened significantly, thus decreasing the atrial and ventricular filling time and increasing systemic venous volume load and central venous pressure [6]. This is accompanied by reversible systolic dysfunction. Insufficient blood supply through coronary arteries to the myocardium during diastole causes relative ischaemia and may cause myopathy. Cardiac dilatation impairs contractility according to Starling's law and dilatation of annulus fibrosus causes atrio-ventricular valve regurgitation. These changes have been referred to as 'tachycardia induced cardiomyopathy' [7]. The resulting heart failure presents as fetal hydrops. Diagnosis is generally incidental in second or third trimester.

The treatment goal is to break the vicious cycle by slowing the heart rate and synchronising atrial and ventricular contractions. This can be achieved by blocking automaticity of ectopic rapidly pacing focus and blocking fast conduction via the accessory pathway. Successful treatment leads to sinus rhythm, disappearance of hydrops and reversal of cardiac dysfunction and ultimate to birth of a live fetus.

Case Report

A 25 Year old 3rd gravida with previous

*Senior Resident,
***Additional Professor,
Department of Obstetrics
and Gynaecology, All India
Institute of Medical
Sciences, Jodhpur.
**Consultant, Soni Maniwal
Hospital, Jaipur.

Pratibha Singh
Addl Prof, Department of
Obstetrics & Gynecology,
AIIMS Jodhpur, Basni
Industrial Area, Phase-2,
Jodhpur, Rajasthan 342005.
E-mail:
drpratibha69@hotmail.com

one term delivery and one abortion at 29 weeks gestation came for routine antenatal check-up and was found to have fetal tachycardia, with heart beats of 220 bpm; which was confirmed by sonography in M mode. Antenatal period was apparently uncomplicated till 29 weeks, and was on regular antenatal visits. There was no maternal or family history of cardiac disease and patient had no fever, anaemia, intake of any drug or excessive caffeine intake or thyrotoxicosis. In her first pregnancy, she

had a full term normal delivery, gave birth to a female child, who is 5 year old without any cardiovascular complication.

On admission fetal heart rate was 220 bpm by fetal doppler. Fetal Echo showed a structurally normal heart with a fetal heart rate of 228 bpm on M mode, and a 1:1 atrioventricular conduction with mild right atrial and right ventricular dilatation and reversal in ductus venosus (Fig 1-4).

Maternal baseline 2 D Echo and ECG, serum

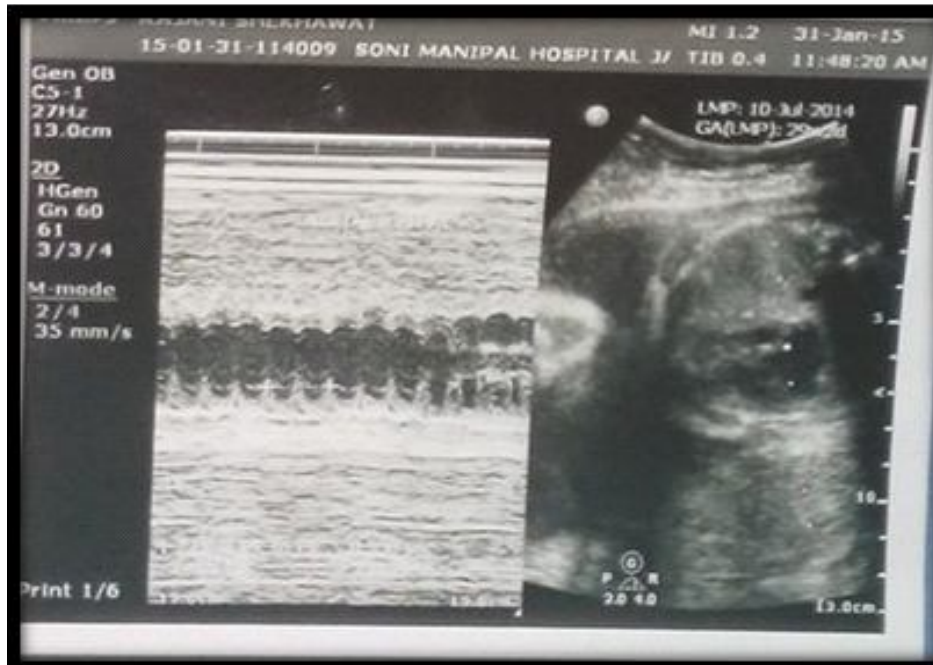


Fig. 1: M-mode showing FHR 228 BPM with 1:1 A-V conduction

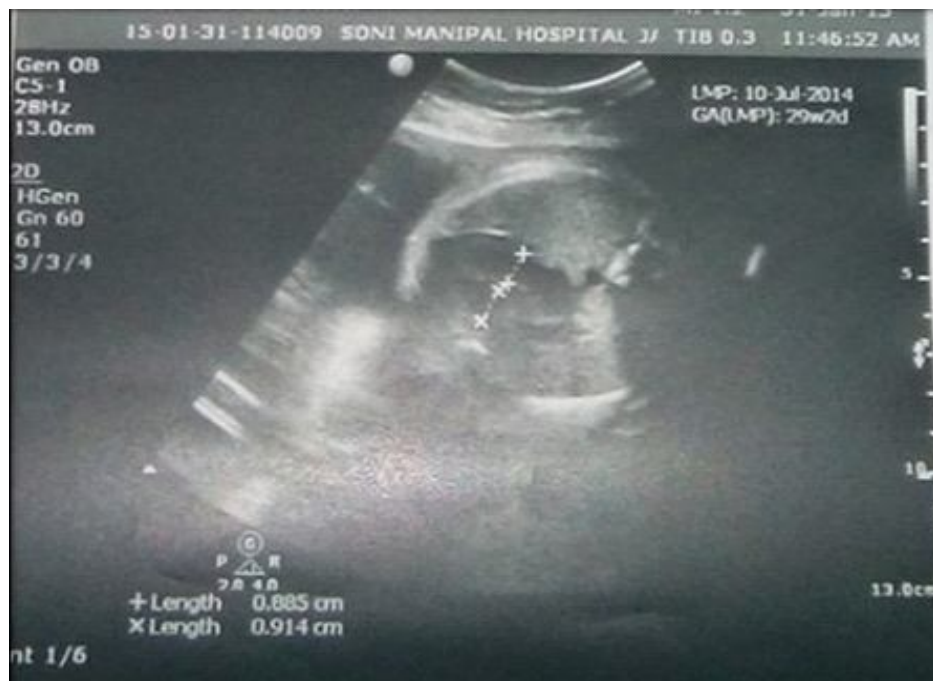

Fig. 2: Mild right ventricular dilatation

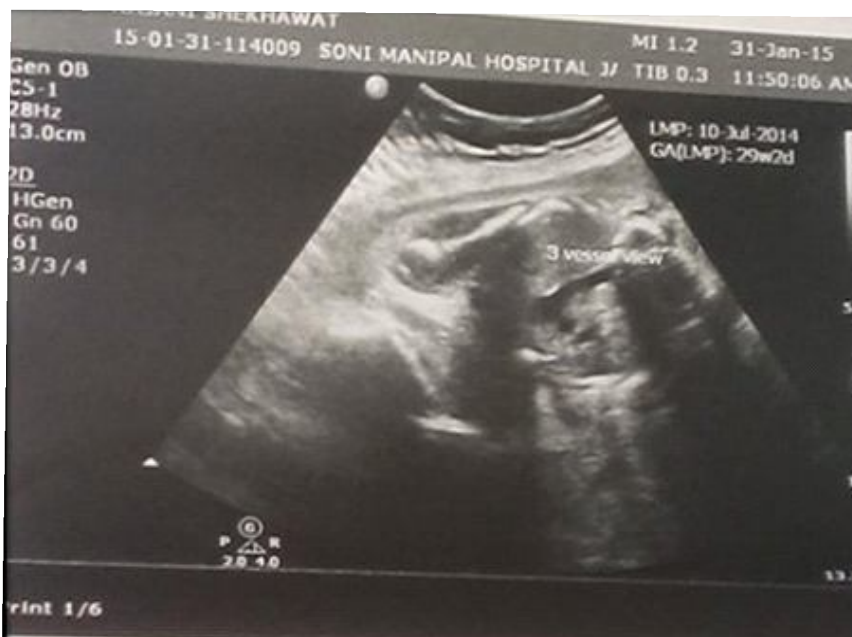

Fig. 3: Structurally normal heart

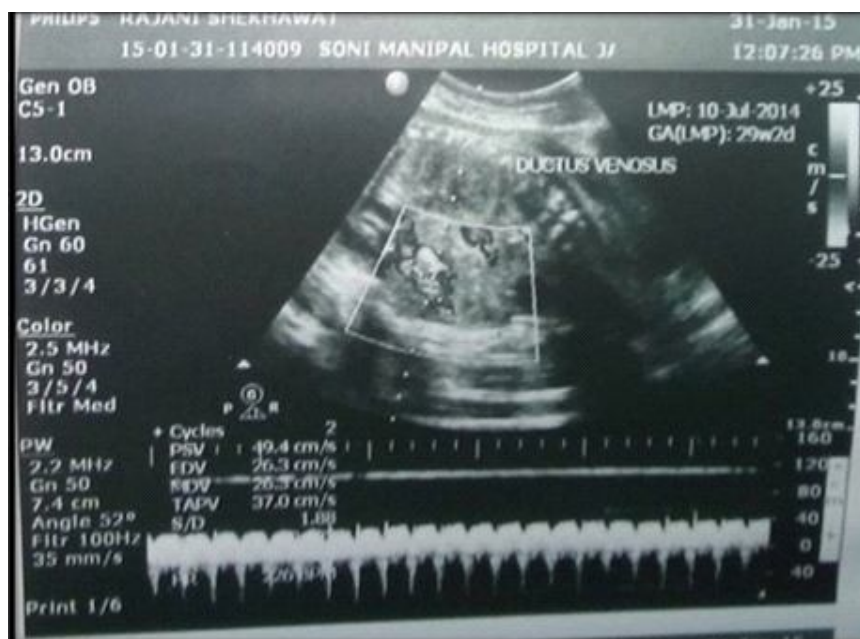

Fig. 4: Reversal in ductus venosus

electrolytes and thyroid profile were done after cardiologist consultation. All the maternal parameters were found to be in normal limits, so she was started on oral digoxin with a dose of 0.25 mg BD. Resolution of tachyarrhythmia was achieved in 72 hours and fetal heart rate reduced to 152 bpm. This dose of 0.25 mg digoxin BD was continued for a week. Normal sinus rhythm of fetus was achieved between 130 to 150 bpm and there was no recurrence of tachyarrhythmia. Dose of digoxin was then reduced to 0.25 mg every 24 hours and patient was kept on fetal surveillance with weekly follow up with no recurrence of SVT till delivery. She underwent an

emergency caesarean section at 39 weeks for foetal distress (Bradycardia with late decelerations on CTG)(Fig.5) and delivered a male baby of 3.5 kg, cried immediately after birth with an APGAR score of 7 and 9 at 1 and 5 minutes. Neonatal Echo was done which showed structurally normal heart with no episode of SVT. Neonatal heart rate remained between 130 to 150 bpm.

After a period of neonatal cardiac monitoring the mother and her baby was discharged on 5th day in stable condition. The neonate on follow up was healthy 28 days after birth without recurrence of arrhythmia.

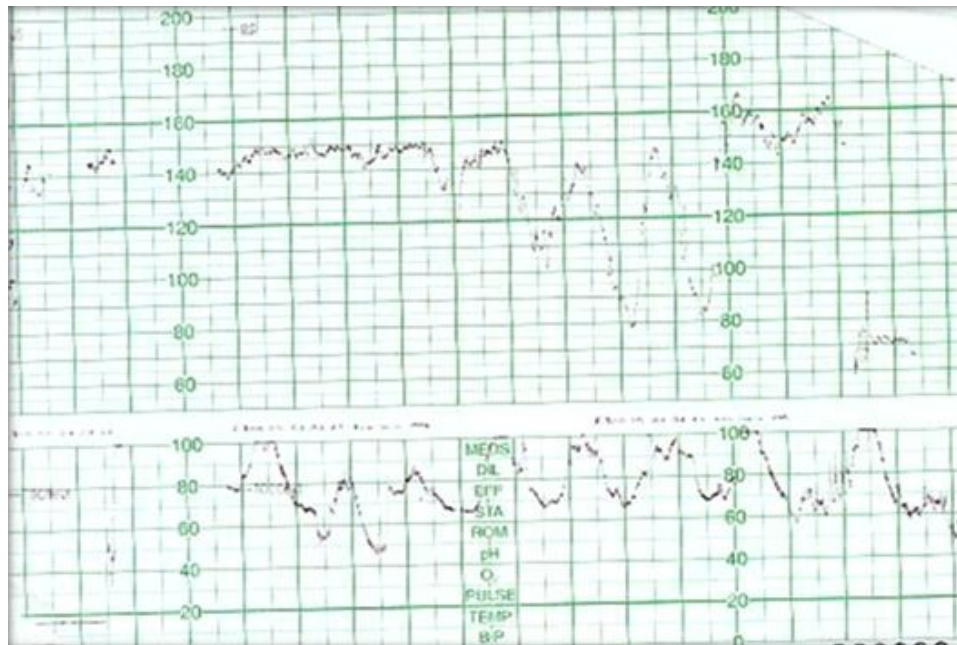


Fig. 5: CTG showing baseline FHR 150 bpm followed by bradycardia and late decelerations

Discussion

Fetal tachycardia was first recognised in 1930 by Hyman et al, which is a condition occurring in approximately 0.4-0.6% of all pregnancies.⁸ Fetal supraventricular tachycardia is a rare but most commonly encountered fetal cardiac arrhythmia in pregnancy that may be associated with adverse perinatal outcome. Excessive caffeine, smoking, drugs, fetal cardiac malformation, and extracardiac malformations like diaphragmatic hernia may contribute to frequent fetal premature atrial contractions which may progress to unrelenting tachyarrhythmia.

There are three forms of abnormal conduction defects which may lead to supraventricular tachycardia. First is atrioventricular nodal re-entrant tachycardia. Extrasystole generates an electric waveform of depolarisation which arrives at the AV node. "Fast tract" within the AV node is refractory to arriving wave while the "slow tract" depolarises again. At precise time the "fast tract" in AV node become repolarised and accepts the waveform from "slow tract" and depolarizes in retrograde fashion, re-entering the atrial tissue. Depolarisation occurs through the fastest conduction pathway available, and so this "circular movement" predominates over the slower impulses generated by sinoatrial node. Second is atrioventricular re-entrant tachycardia, same "circular movement" is established, but "fast

tract" limb occurs outside the atrioventricular node. This pathway directly connects the atria and ventricle and is known as Wolff-Parkinson-White Syndrome. The third mechanism of SVT is automatic atrial tachycardia resulting from discreet pacemaker within the atrium outside the sinoatrial node. Atrial flutter and fibrillation results from "circular pathway" within the atria themselves ruled out in an indirect fashion.

There is no proper guidelines regarding start of therapy and mode of application, so management must be individualised [3]. Digoxin is widely accepted as anti arrhythmic drug of choice in non-hydrops fetus [9]. Digoxin is cardiac glycoside that partially blocks conduction through atrioventricular node [10]. It terminates "circular movement" within re-entrant circuits by prolonging the refractory phases that the aberrant wave of excitation reaches depolarised tissue. Recent studies show a high fetal mortality rate of 27% to 50% without treatment as compared to 5% to 10% when anti arrhythmic was administered [11]. Second line medication as sotalol, depresses AV nodal conduction, produce an increase in duration of action potential and lengthen the effective and absolute refractory period [12].

Potential pro-arrhythmic action of sotalol remain a source of concern and excludes it as a drug of first choice in uncomplicated SVT. In case of severe hydrops and poor cardiac function, due to its negative inotropic effect, the drug should always be administered in association with digoxin. Flecainide,

another anti-arrhythmic which depresses conduction throughout myocardium and prolongs the refractory period is mainly used in fetal SVT complicated by hydrops. Amiodarone which prolongs repolarisation has gained popularity. However adverse effects are of concern (mainly neonatal hypothyroidism) and hence should be used as second line therapy [13].

The management depends upon the age of gestation and presence of hydropic features. In non hydropic foetus with fetal lung maturity (>34 weeks gestation) delivery with evaluation of neonate can be considered. Combination drug therapy reduces the dose, increases effectiveness and decreases side effect in hydropic infant. Maternal administered oral drug therapy crosses transplacentally to the foetus and has anti arrhythmic action. Oral digoxin avoids the need of therapeutic drug-level monitoring, which is required in intravenous therapy. Direct fetal therapy should only be used in cases of tachycardia complicated with hydrops resistant to transplacental multidrug therapy.

The optimal duration of treatment of prenatally diagnosed supraventricular tachycardia remains undetermined. Most reported cases treatment was continued until birth, newborns are treated with beta blocker if SVT recurs early after birth or is easily inducible during transesophageal electrophysiologic study [4].

Postnatal recurrence of arrhythmia has been described in approximately 50% of neonates [14]. Some favour prophylactic continuation of drug during first 6-12 months of life to prevent recurrence [15]. In 10-20% of cases, SVT will persist beyond first year of life [14].

Timely diagnosis, ruling out other cardiac and non cardiac problems by appropriate investigations; and timely and correct therapy not only saves the fetus but also gives a good prognosis to these fetuses

References

- Merriman JB, Gonzalez JM, Rychik J. Can sotalol and digoxin therapy for fetal supraventricular tachycardia and hydrops be successful? *J Reprod med.* 2008; 53(5): 357-59.
- Lisa M Jones, Sara H Garmel. Successful digoxin therapy for fetal supraventricular tachycardia. *obstetrics and gynaecology.* 2001; 98: 921-23.
- Strasburger JF. Fetal arrhythmias. *Progr Pediatr Cardiol.* 2000; 11: 1-17.
- Jaeggi ET, Nii M. Fetal brady- and tachyarrhythmias: New and accepted diagnostic and treatment methods. *Semin Fetal Neonatal Med* 2005;10:504-14.
- Lingman G, Ohrlander S, Ohlin P. Intrauterine digoxin treatment of fetal paroxysmal tachycardia. Case report. *Br J ObstetGynaecol.* 1980.
- Gembruch U, Krapp M, Baumann P. Changes of venous blood flow velocity waveforms in fetuses with supraventricular tachycardia. *Ultrasound Obstet Gynecol.* 1995; 5: 394-399.
- Krapp M, Gembruch U, Baumann P. Venous blood flow pattern suggesting tachycardia-induced 'cardiomyopathy' in the Fetus. *Ultrasound obstet gynecol.* 1997; 10: 32-40.
- Rana Y.S., Sodhi B, Kochar SPS, Arora D. Successful digoxin therapy of fetal supraventricular tachycardia. *South Asian Federation of Obstetrics and Gynaecology.* Jan-Apr 2009; 1(1): 44-46.
- Simpson JM, Sharland GK. Fetal tachycardias: management and outcome of 127 consecutive cases. *Heart.* 1998; 79: 576-581.
- Goodman DJ, Rossen RM, Cannom DS, Rider AK, Harrison DC. Effect of digoxin on atrioventricular conduction. Studies in patients with and without cardiac autonomic innervation. *Circulation* 1975; 51: 251-256.
- Strasburg JF, Cheulkar B, Wichman HJ. Perinatal arrhythmias: diagnosis and management. *Clin Perinatol.* 2007; 34: 627-52.
- V Samuel Rajadurai, Samuel Menahem. Fetal arrhythmias: a 3-year experience. *Australian and New Zeland Journal of Obstetrics and Gynaecology.* 2008; 32: 28-31.
- Pradhan M, Manisha, Singh R. Amiodarone in treatment of supraventricular tachycardia. *Fetal Drug Ther.* 2006; 21: 72-76.
- Hansmann M, Gembruch U, Bald R, Manz M, Redel DA. Fetal tachyarrhythmias: transplacental and direct treatment of the fetus – a report of 60 cases. *Ultrasound Obstet Gynecol.* 1991; 1: 162-170.
- Simpson J. Fetal arrhythmia. In *Textbook of fetal cardiology*, Allan L, Hornberger L, Sharland G (eds). Greenwich Medical Media: London. 2000; 423-451.